

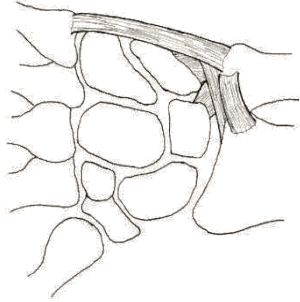


EFSHT Cheat Card

Interested in becoming an European Certified Hand Therapist?

www.eurohandtherapy.org

echt@eurohandtherapy.org



Triangular fibrocartilage complex

TFCC lesions classification (Palmer AK)

The TFCC:

The TFC (triangular fibrocartilage): the discus articularis between the proximal row and the ulnahead

- The dorsal and palmar radio-ulnar ligaments
- The ulno-carpal ligaments on the palmar and ulnar side
- The tendonsheet of the ECU

Type 1 Acute traumatic tears

- 1A Central TFC perforation
- 1B Peripheral ulnar side TFCC tear (+/- ulna styloid fracture)
- 1C Distal TFCC disruption (disruption from distal ulnar ligaments)
- 1D Radial TFCC disruption (+/- sigmoid notch fracture)

Type 2 Degenerative

- 2A TFCC wear
- 2B TFCC wear with lunate and/or ulnar chondromalacia
- 2C TFCC perforation with lunate and/or ulnar chondromalacia
- 2D TFCC perforation with lunate and/or ulnar chondromalacia with LTIOL
- perforation
- 2E 2D + ulnocarpal arthritis